

Magnesium for Reduction of Pulmonary Artery Pressure in Primary Pulmonary Hypertension

M. Shechter, S. Rosenblatt, M. Motro, B. Rabinowitz, E. Kaplinsky, O. Agranat

Zusammenfassung

Magnesium ist ein physiologischer Calcium-antagonist und als hochwirksamer Vasodilatator sowohl *in vitro* [1] als auch *in vivo* [2] beschrieben worden. Desungeachtet ist – nach unserem Wissen – sein Einfluß auf den menschlichen Lungenkreislauf bei Patienten mit primärem Lungenhochdruck (PPH) bis heute noch nicht beschrieben worden.

Wir schildern den Fall einer jungen Frau mit PPH, die mit einer Kombination von Nifedipin und Magnesium behandelt wurde. Diese kombinierte Therapie resultierte in einer deutlicheren Reduzierung des Lungenarteriendruckes (PAP), verglichen mit einer Behandlung mit jeweils nur einem der beiden Präparate. Die Therapiewirkung ermöglichte es der Patientin, auf eine Herz- und Lungentransplantation zu warten.

Summary

Magnesium is a physiological calcium antagonist and has been described as a potent vasodilator *in vitro* [1] and *in vivo* [2], nevertheless to the best of our knowledge, its influence on human pulmonary circulation in patients with primary pulmonary hypertension (PPH) has not been described yet.

We describe a young woman with PPH who was treated with a combination of nifedipine and magnesium. The combined therapy resulted in a more pronounced reduction in pulmonary artery pressure (PAP) compared with either drug used alone and its efficacy enabled the patient to await heart and lung transplantation.

Résumé

Le magnésium est un antagoniste physiologique de calcium qui a été décrit comme un vasodilatateur efficace *in vivo* [1] et *in vitro* [2]. Néanmoins – à notre connaissance – son influence sur la circulation pulmonaire humaine chez des patients souffrant d'une hypertension pulmonaire primaire (PPH) n'a pas encore été décrit.

Nous détaillons le cas d'une jeune femme qui souffrait de PPH et qui était traitée d'une combinaison de Nifédipine et Magnésium. Cette thérapie combinée résultait dans une réduction plus marquée de la pression de l'artère pulmonaire, en comparaison du traitement de chacun de ces deux médicaments, pris seuls à la fois. L'efficacité de ce traitement donnait à la jeune femme la possibilité d'attendre une transplantation du coeur et du poumon.

Case Report

A 21 year-old woman suffering from PPH diagnosed one month previously, was admitted because of increasing shortness of breath and near syncope on effort. Physical examination revealed blood pressure of 105/70, and pulse rate of 64/min. A pronounced right ventricular parasternal heave was palpated and a second loud heart sound was heard over the pulmonary artery area. There were no clinical findings of right or left heart failure. ECG showed right ventricular hypertrophy. Chest X-ray revealed enlargement of the right ventricle and pulmonary artery. Pulmonary function tests were normal. Two dimensional echocardiography (2DE) demonstrated a markedly

enlarged right ventricle and pulmonary artery. PAP calculated by Doppler echocardiography (DE) [3, 4] was 58 mm Hg. Blood count, electrolytes, liver function tests and cardiac enzymes were normal. Right heart catheterization revealed PAP of 64/24 mm Hg (mean 36), right atrial pressure (RAP) 9 mm Hg, cardiac output (CO) 5.4 liter/min, mean pulmonary capillary wedge pressure (CWP) 9 mm Hg, systemic vascular resistance (SVR) 1244 dynes. sec.cm^{-5} and pulmonary vascular resistance (PVR) 400 dynes. sec.cm^{-5} . Following diltiazem 240 mg/day PAP remained 64/24 mm Hg (mean 28), SVR dynes. sec.cm^{-5} , PVR 240 dynes. sec.cm^{-5} and CO 6.1 liter/min. After discontinuation of diltiazem, a single dose of 20 mg nifedipine reduced PAP to 73/13 mm Hg (mean 22), CWP 7 mm Hg, RA 6 mm Hg, SVR 880 dynes. sec.cm^{-5} . Systolic blood pressure also dropped to 90 mm Hg with sympto-

matic sinus tachycardia of 130 bpm. There were facial flushing and headaches. The patient was discharged on nifedipine 10 mg Q.I.D. and warfarin according to prothrombin time. During the following months the patient improved clinically and PAP calculated by DE remained low.

Six months later the patient was readmitted because of recurrent episodes of syncope upon minimal effort. On admission blood pressure was 100/60 mm Hg, heart rate 90 beats per minute. Physical examination remained unchanged. PAP calculated by DE was 97–100 mm Hg.

Nifedipine (in oral doses of 40 to 150 mg per day) and magnesium intravenously (11 g per day) or orally (Magnesiocard [magnesium-L-aspartate-HCl.3 H₂O] 15 mmol per day, Verla-Pharm, Tutzing, Germany) alone and in combination were administered and the patient was followed clinically

Heart Institute, Sheba Medical Center and Sackler School of Medicine, Tel-Aviv University (Israel).

Magnesium for Reduction of Pulmonary Artery Pressure in Primary Pulmonary Hypertension

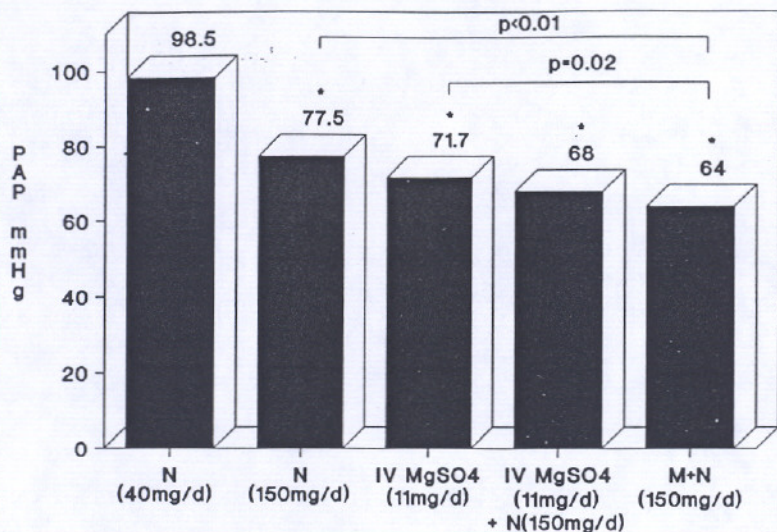


Fig. 1: Pulmonary artery pressure (PAP) in various treatment schedules.

Oral nifedipine (150 mg/d) or IV MgSO₄ (11 mg/d) alone reduced PAP by 22% and 28% respectively. The combination therapy of oral nifedipine with either IV MgSO₄ or oral magnesium (Magnesiocard) further reduced PAP by 32% and 36% respectively.

N = Nifedipine-Oral; M = Magnesiocard (magnesium-L-aspartate-hydrochloride) Oral (15 mmol/d); * = A significant change from baseline ($p < 0.01$).

and by repeated DE assessment (Fig. 1). Nifedipine or magnesium alone reduced PAP from 98.5 to 77.5 mm Hg or 71.7 mm Hg respectively ($p < 0.01$). The combination of nifedipine and magnesium (intravenously or orally) significantly reduced PAP to 64–68 mm Hg ($p < 0.01$), while systemic blood pressure remained 90/60 mm Hg and the patient suffered no more episodes of syncope on effort.

The addition of magnesium to nifedipine caused a further significant reduction in PAP without any adverse effects and enabled her to live almost free of symptoms for another seven months. Unfortunately, she eventually died while waiting in another country for a suitable heart and lung donor.

Discussion

The syndrome of PPH is probably the final common pathway for multiple etiologies and diverse pathogenetic sequences [5]. The aim of pharmacologic therapy in PPH is to induce pulmonary vasodilation and reduce the work-

load of the right ventricle. However, no single vasodilator has yet been consistently successful in achieving this goal [6].

Currently there is no ideal pulmonary vasodilating agent available for either acute or chronic administration by oral route [7]. Prognosis remains poor and the disease often pursues a relentless course ending in circulatory failure [5]. Magnesium was demonstrated to relax smooth muscles in rats' aorta [1], in human umbilical vessels [8] and in coronary arteries [2]. Studies on experimental animals have shown that disturbances of magnesium metabolism may have profound effects on the contractile state of vascular smooth muscle and thus on blood pressure [9]. There are several reports on the clinical and hemodynamic effects of magnesium in man. Magnesium sulfate controls convulsions and high blood pressure in eclampsia [10]. Right heart catheterization in patients with acute myocardial infarction demonstrated 13–15% reduction in PVR and a 7–17% reduction in PAP [11].

In our patient either nifedipine or magnesium alone reduced PAP by 22% and 28% respectively: Oral nifedipine reduced PAP from 100 mm Hg to 77.5 mm Hg ($p < 0.01$), and intravenous magnesium reduced it to 71.7 mm Hg ($p < 0.01$). The combination therapy of oral nifedipine with intravenous magnesium reduced PAP significantly from 100 mm Hg to 68 mm Hg, and with oral magnesium to 64 mm Hg (a reduction of PAP by 32% and 36% respectively; $p < 0.01$), thus, the administration of magnesium to patients with PPH may help carry them through the waiting period until heart-lung transplantation.

References

- [1] *Altura, B. M.; Altura, B. T.*: Magnesium withdrawal and contraction of arterial smooth muscle: effects of EDTA, and divalent 3 cations. *Science* 151 (1976) 752–55.
- [2] *Turlapaty, P. D. M. V.; Altura, B. M.*: Magnesium deficiency produces spasms of coronary arteries: Relationship to etiology of sudden ischemic heart disease. *Science* 208 (1980) 198–20.
- [3] *Yock, P. G.; Popp, R. L.*: Non-invasive estimation of right ventricular pressure by Doppler ultrasound in patients with tricuspid regurgitation. *Circulation* 70 (1984) 657–62.
- [4] *Berger, M.; Haimowitz, A.; Van Tosh, A. et al.*: Quantitative assessment of pulmonary hypertension in patients with tricuspid regurgitation using continuous wave Doppler ultrasound. *J. Am. Coll. Cardio.* 6 (1985) 359–63.
- [5] *Pietra, G. G.; Edwards, W. D.; Kay, M. et al.*: Histopathology of primary pulmonary hypertension. A qualitative and quantitative study of pulmonary blood vessels from 58 patients in the National Heart, Lung and Blood Institute, Primary Pulmonary Hypertension Registry. *Circulation* 80 (1989) 1198–206.
- [6] *Palevsky, H. I.; Schloo, B. L.; Pietra, G. G. et al.*: Primary pulmonary hypertension. Vascular structure, morphometry, and responsiveness to vasodilator agents. *Circulation* 80 (1989) 1207–21.
- [7] *Palevsky, H. I.; Fishman, A. P.*: Vasodilator therapy for primary pulmonary hypertension. *Annu. Rev. Med.* 36 (1985) 563–78.
- [8] *Altura, B. M.; Altura, B. T.; Carrella, A.*: Magnesium deficiency-induced spasms of umbilical vessels: Relation to preeclampsia, hypertension, growth retardation. *Science* 221 (1983) 376–78.

Magnesium for Reduction of Pulmonary Artery Pressure in Primary Pulmonary Hypertension

- [9] *Dyckner, T.; Wester, P. O.*: Effects of magnesium on blood pressure. *BMJ* 286 (1983) 1847-49.
- [10] *Pritchard, J. A.; Cunningham, F. G.; Pritchard, S. A.*: The Parkland Memorial Hospital protocol for treatment of eclampsia: Evaluation of 245 cases. *Am. J. Obstet. Gynecol.* 148 (1984) 951-60.
- [11] *Rasmussen, H. S.*: Justification for intravenous magnesium therapy in acute myocardial infarction. *Magnesium Research I* (1988) 59-73.

Correspondence to:
Michael Shechter, MD, Cedars Sinai Medical Center, Mark Goodson Building, Room # 901, 444 South San Vincent Blv., Los Angeles, CA 90048, USA